

Clinical Detection and Decision-Making Considerations for Cracked Teeth

Mitchell H. Davich, DMD, FACD, FICD*

FIGURE. Illustration demonstrates the theory that endodontic reality is largely based on findings described in clinical research, not studies, as opposed to empiricism and theory.

Since Cracked Tooth Syndrome was described 40 years ago,¹ numerous advancements in endodontic treatment and technology have occurred. Yet practitioners still remain perplexed regarding the detection of cracked teeth, perhaps because patients' symptoms are often vague and radiographs are usually normal. This resulting delay in diagnosis and treatment can allow further longitudinal progression of the fracture, both in time and spatial dimension,² leading to eventual extraction. In industrialized nations, fractured teeth have been reported to be the third-most common cause of tooth loss.³

Given that presenting symptoms may be described only as a momentary unlocalized sensitivity to chewing or a brief thermal sensitivity, practitioners need to consider certain predisposing conditions that may help direct them toward the proper diagnosis of a cracked tooth. Correct diagnosis of a fractured tooth in its earliest possible stage encourages more conservative treatment options as well as an improved prognosis.

Undiagnosed or misdiagnosed fractures create delays, allowing the proliferation of fractures, and may thereby lead to more extensive treatment and an unfavorable outcome. Since the ultimate goal for the patient and dental practitioner alike is the preservation of the natural tooth, early and rapid treatment of cracked teeth is essential.

Ten common characteristics are associated with cracked teeth (table). These signs may occur by themselves or in combination with others on the list.

In Hiatt's study, 74% of cracked teeth had no proximal restorations, and 71% of fractures were found in mandibular molars.⁹ Sylvestri theorized that continued masticatory forces on MOD preparations created internal shearing forces, thus predisposing teeth to off-center oblique cuspal fractures.⁵

Plunger cusps can be associated with various malocclusions and premature tooth loss. These, together with steep cuspal

inclines, create a "hammer and anvil" chewing effect that can generate or propagate a crack.

Patients with enlarged, overdeveloped masticatory muscles usually present a "square jaw" appearance. One can sometimes observe the tensing of their hypertrophic masseter and temporalis muscles, as if these patients are chewing gum while sitting in the dental chair.

Diets abundant in abrasive foods, such as rice, grains, and raw vegetables, predispose teeth to premature occlusal wear, thus weakening their cuspal integrity. Brow found that teeth subjected to thermal cycling between 90 and 140 degrees had severe cracking.¹⁰ Consequently, a habit such as ice chewing generates optimal conditions for the creation and proliferation of tooth fractures.

Patients presenting for cracked tooth evaluation often report a previous history of a fractured tooth. In several instances, the previously cracked tooth is the contralateral tooth to the one currently being examined for

fracture. Posterior teeth without full-coverage restorations that have undergone endodontic therapy require cuspal fracture protection with a permanent restoration, usually within one month of endodontic completion. Delaying permanent restorations or merely filling access openings with amalgam or composite unnecessarily exposes endodontically treated teeth to the risk of fracture.

Abfraction lesions,⁷ also called noncarious cervical lesions (NCCL), are wedge-shaped circular invaginations that were once thought to be related to toothbrush abrasion (Figures 1 through 4). They are now known to be associated with occlusal wear facets 94.5% of the time and with a lack of canine-guided occlusion 77.2% of the time.⁶ Excessive occlusal loading and flexure due to wear of the dentition have been suggested as possible causes for fracture of a sometimes

unrestored tooth with an abfraction lesion. Controversy still exists regarding whether or not to restore abfraction lesions, but an examination of the occlusal pattern and mitigation of forces involved is of paramount importance in preventing fractures of teeth with abfractions.

Due to improvements in adhesive dentistry, intracoronary pin buildups for core retention are not as common as in the past. These buildups produce internal dentinal cracks during pin insertion, which can propagate laterally and apically, depending upon the demands placed on the restoration.⁸ For this reason, the use of pins to reinforce buildups is now discouraged.

DETECTION

Patients with fractured teeth usually report episodic vague and unlocalized symptoms,

making it difficult to determine the presence or location of a tooth fracture. In addition, radiographic detection of cracked teeth is difficult since most fractures are incomplete and are surrounded by normal tooth structure somewhere either buccally or lingually. Unless the central ray is exactly parallel to the crack, it will not be visible on a periapical or bitewing radiograph. Sometimes, software enhancement tools within digital radiography systems aid in the evaluation of radiographic images (Figures 5 through 8). Direct visualization remains the most reliable method for fracture diagnosis. Below is a list of some clinical aids available for improving visualization of fractures.

1. Indirect illumination. This can be accomplished with a battery-powered inspection light, a fiber-optic light, or an eye-protected curing light by placing the illumination

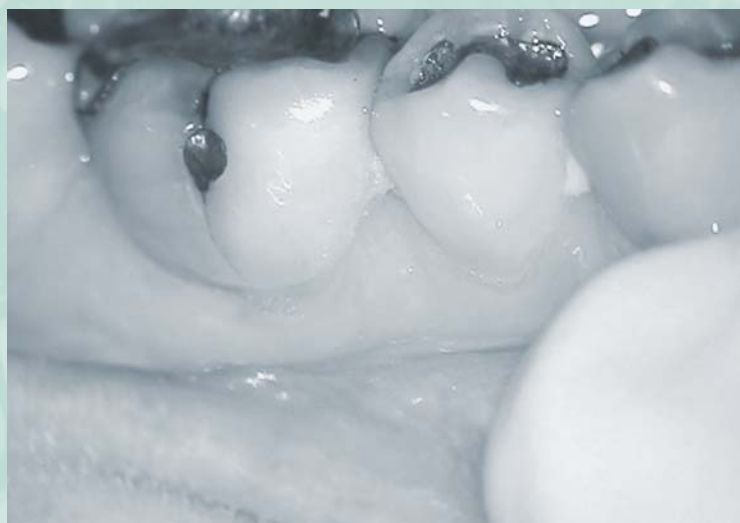

Figure 1. Case 1. Dark, stained fracture line extends through buccal groove and connects to abfraction lesion on buccal of tooth #30(46). Additional fracture line can be seen on the mesial marginal ridge.

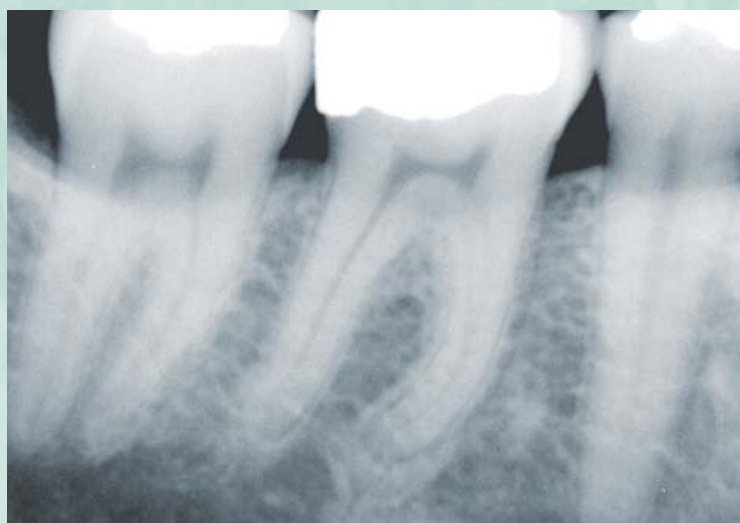


Figure 2. Radiograph denotes deep restoration of longstanding duration. Referring dentist saw no pathology and thought it best to observe since the amalgam restoration was intact.

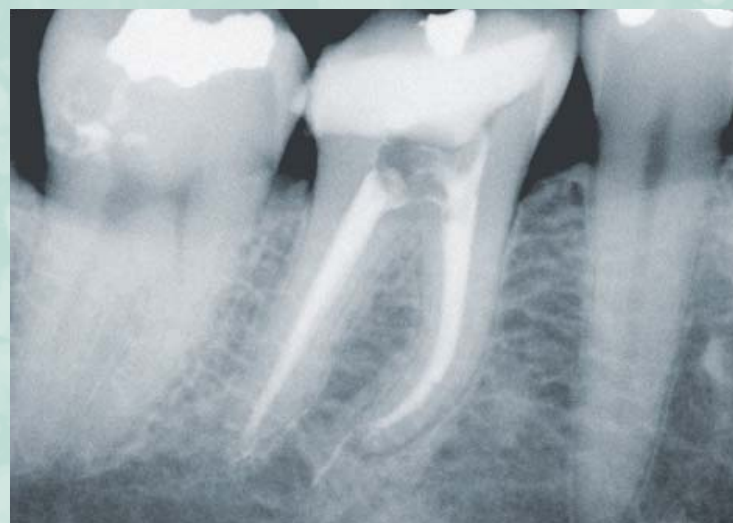

Figure 3. Radiograph after completion of endodontic therapy. Nondisplaceable vertical fractures were found buccolingually and mesiodistally.

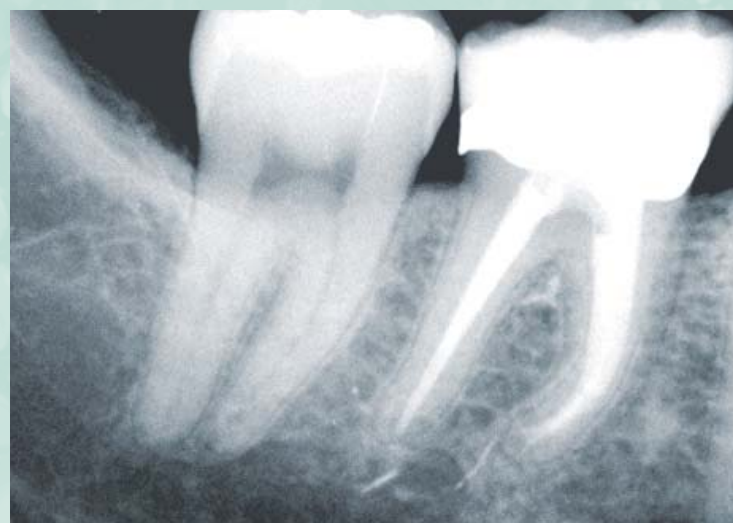

Figure 4. One-year recall radiograph shows normal periapex. Tooth was restored with bonded core and full-coverage crown and is asymptomatic.

source against the buccal or lingual surface of the tooth. If the beam of light passes through uninterrupted, this is usually a sign of a shallow enamel craze line. If, however, the light beam does not pass totally through to the other side, leaving one side light and the other dark, this is often an indication that an internal fracture exists.¹¹

2. Microscopic examination. The use of the surgical operating microscope with its improved magnification to 16 \times and illumination has made it possible for much better visualization of structural defects in teeth and restorations than with magnifying loupes or the naked eye. Valuable information can be gathered from microscopic examination, which may help point the way toward correct fracture diagnosis.

3. Staining. Various dyes can be used to stain for direct visualization of fractures.

They include: methylene blue, iodine, and caries detection dye.

4. Chewing test. A cotton roll selectively moved from tooth to tooth while the patient is chewing can help to pinpoint the general location of a crack. It may not, however, always be possible to identify in which arch the offending tooth exists.

5. Hard bite test. A "Tooth Slooth," "Fracture-Finder," or wooden bite stick are indispensable diagnostic tools for fracture detection. By placing the concave end against individual cusp tips, pain is often experienced when releasing the bite, presumably because fluid within the fracture moves pulpally. This particular reaction appears to be a unique feature of fractured teeth.

6. Exploratory excavation. Sometimes exploratory excavation becomes necessary to obtain a visual diagnosis (Figures 9 through

13). The decision to excavate should always be made with the consent of the patient, since it is not guaranteed that a fracture will be found underneath any removed restoration.

EXTRACTION VERSUS RETENTION

Symptomatic fractures have been shown to extend through the dentin and to be extensively contaminated by bacteria.¹² It is unlikely that this bacterial contamination can be fully eradicated by sealants and restorative materials. Even if symptoms temporarily abate after excavation and temporization, these teeth will eventually require endodontic therapy and should be considered for immediate treatment to minimize subsequent pulpal and periapical breakdown and to maximize chances of tooth retention.

Once a fracture has been visualized, a determination of its longitudinal depth and

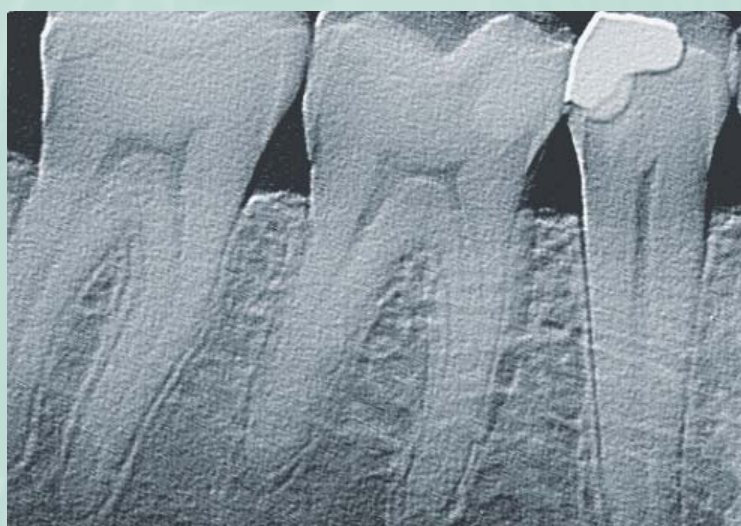


Figure 5. Case 2. The patient's right temporalis and right external pterygoid muscles were tender to palpation. Fracture testing indicated sensitivity on the distolingual surface of tooth #31(47). Pulp tests were normal for tooth #30 and #31, but patient declined treatment initially.

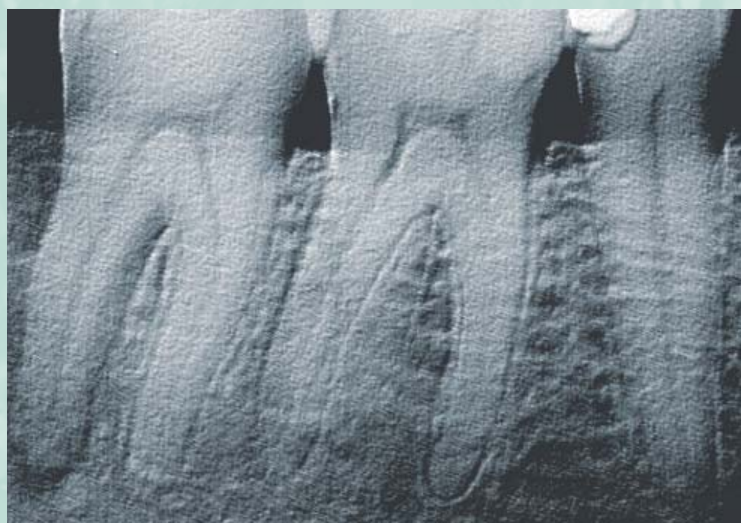


Figure 6. Three months later, patient was unable to function on tooth #31 which was sensitive to heat and cold. Radiographically, an endo-perio lesion with extensive bone loss was noted to encompass the distal root from apex to gingival crest.

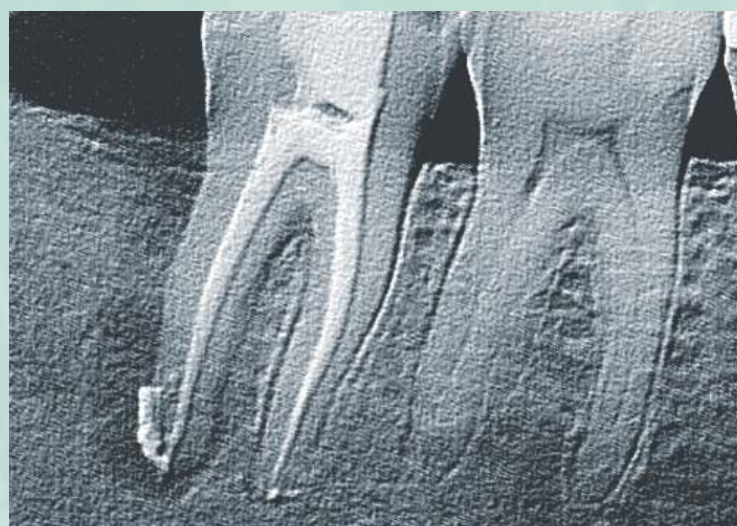

Figure 7. Postoperative radiograph shows bone loss into furcation and length of distal root. A nondisplaceable mesiodistal fracture was found. Surplus sealer was extruded beyond apex of distal root during obturation.

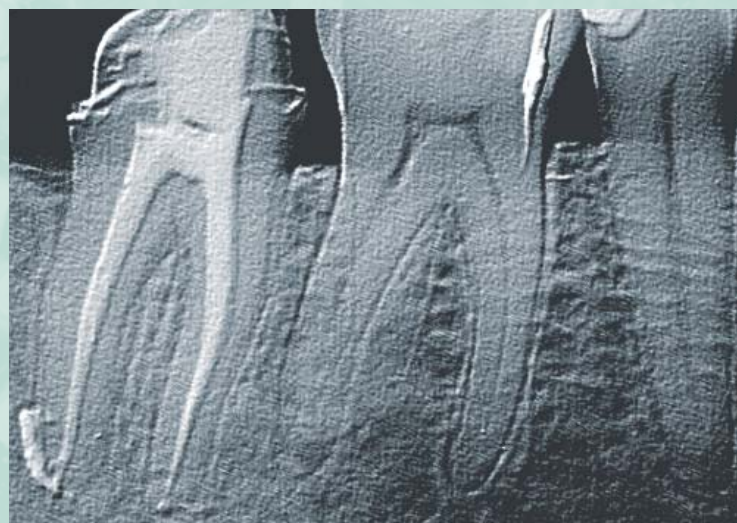


Figure 8. Six-month recall radiograph shows complete healing. The tooth was immediately provisionalized with an acrylic crown after endodontic therapy and is now asymptomatic.

separability should be made. Fractures that extend below the furcation floor or into the periodontium usually have a diminished prognosis and should be considered for extraction, but can sometimes be treated with the patient's informed consent, always keeping in mind the goal of preserving the natural tooth.

If a horizontal or oblique cuspal fracture is present, it must be removed and the tooth assessed for restorability. Additional periodontal crown lengthening may be required. Most of these teeth are treatable, however, and should be retained.

Regarding a mesiodistal or buccolingual fracture, excavation should take place to the depth of a Class II preparation; removal of the entire fracture may not be feasible in this situation. The displaceability can be checked with a spoon excavator or similar instrument. If the fractured segments can be separated, then the prognosis is poor and extraction should be considered. If the fractured segments are not displaceable, a bonded core and provisional crown should be placed as soon as possible after endodontic therapy.

It is feasible that additional fracture resistance may be obtained by using currently available endodontic sealers containing glass and resin ionomers.¹³ Recently, a soft resin endodontic obturation system was introduced. Long-term clinical studies will be

necessary to determine whether this material can better protect an endodontically treated cracked tooth from further injury and ultimately enhance the prognosis of these teeth.

CONCLUSION

Fractured teeth present both a diagnostic and treatment dilemma. Practitioners should familiarize themselves with certain predisposing factors that may aid in fracture detection and diagnosis. Early and rapid treatment of cracked teeth is essential for a favorable outcome. Delayed or partial treatment worsens the prognosis by allowing fractures to proliferate. Treatment protocol for cracked teeth depends upon the direct visualization of the fracture. The decision to extract or retain such teeth varies according to the location, displaceability, degree of periodontal involvement, as well as the patient's desire to retain the natural tooth for as long as possible. ■

REFERENCES:

1. Cameron CE. Cracked-tooth syndrome. *J Am Dent Assoc* 1964;68:405-411.
2. Rivera EM, Williamson A. Diagnosis and treatment planning: Cracked tooth. *Tex Dent J* 2003;120(3):278-283.
3. Geurtsen W, Schwarze T, Gunay H. Diagnosis, therapy, and prevention of the cracked tooth syndrome. *Quint Int* 2003;34(6):409-417.
4. Ratcliff S, Becker IM, Quinn L. Type and incidence of cracks in posterior teeth. *J Prosthet Dent* 2001;86(2):168-172.
5. Silvestri AR. The undiagnosed split-root syndrome. *J Am Dent Assoc* 1976;92(5):930-935.
6. Miller N, Penaud K, Ambrosini P, et al. Analysis of etiologic factors and periodontal conditions involved with 309 abfractions. *J Clin Periodontol* 2003;30(9):828-832.
7. Owens BM, Gallien GS. Noncarious dental "abfraction" lesions in an aging population. *Comp Dent Educ* 1995;16(6):552, 554, 557-558.
8. Standlee JP, Collard EW, Caputo AA. Dentinal defects caused by some twist drills and retentive pins. *J Prosthet Dent* 1970;24(2):185-192.
9. Hiatt WH. Incomplete crown-root fracture in pulp-periodontal disease. *J Periodontol* 1973;44(6):369-379.
10. Brown WS, Jacobs HR, Thompson RE. Thermal fatigue in teeth. *J Dent Res* 1972;51(2):461-467.
11. Liewehr FR. An inexpensive device for transillumination. *J Endod* 2001;27(2):130-131.
12. Kahler B, Moule A, Stenzel D. Bacterial contamination of cracks in symptomatic vital teeth. *Aust Endod J* 2000;26(3):115-118.
13. Trope M, Tronstad L. Resistance to fracture of endodontically treated premolars restored with glass ionomer cement or acid etch composite resin. *J Endod* 1991;17(6):257-259.

*Private practice, Morristown, NJ. He may be contacted at MDAVICHMD@aol.com.

10 Red Flags Associated with Cracked Teeth

- 1) Class I restoration with excursive interference.⁴
- 2) Class II restoration with inadequate cuspal protection.⁵
- 3) Plunger cusp and/or malocclusion.
- 4) Steep cuspal inclines.
- 5) Hypertrophic masticatory muscles.
- 6) Abrasive diet and/or parafunctional habit.
- 7) Previous history of cracked tooth.
- 8) Unrestored root-canal-treated tooth.
- 9) Abfraction lesion (NCCL).^{6,7}
- 10) Intracoronal pins.⁸



Figure 9. Case 3. A symptomatic fracture was found on tooth #14(26), which was prepared for a crown. When the symptoms did not resolve, the patient was referred for endodontic evaluation and treatment.

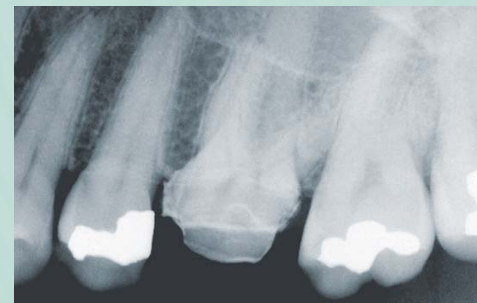

Figure 10. Occlusal view of tooth prior to excavation. Superficial dark-stained vertical fracture line is seen mid-palatally along outside surface of crown.



Figure 11. Fracture is excavated with round bur and extends into middle of crown both buccolingually and corono-apically.

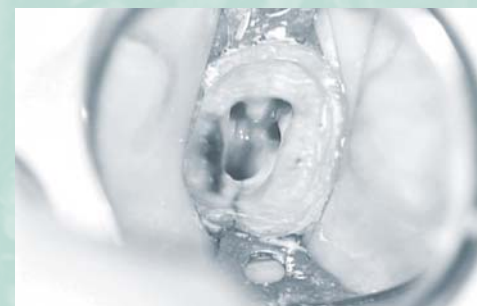

Figure 12. Fracture extends into pulp chamber but is nondisplaceable and does not involve furcal floor. Prognosis for successful endodontic therapy is favorable. This view also shows the orifices, for four canals prior to obturation.

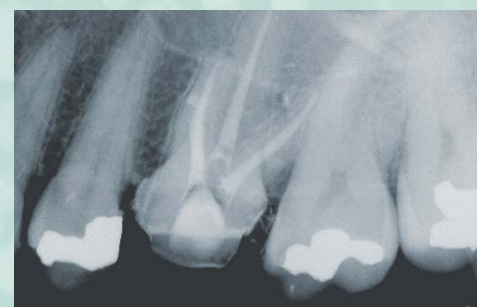

Figure 13. Postoperative image following obturation. Tooth was eventually restored with a bonded core buildup and full-coverage restoration.